

## A New Approach for Treatment and Prevention of Recurrent Oral Lichen Planus: A Technical Report

F. Agha-Hosseini<sup>1</sup>, M-S. Moosavi<sup>2</sup>, R. Varshochian<sup>3</sup>, Kh. Akbari<sup>4</sup>✉.

<sup>1</sup> Professor, Dental Research Center, Dentistry Research Institute, Tehran University of Medical Sciences, Tehran, Iran, AND Department of Oral Medicine, School of Dentistry, Tehran University of Medical Sciences, Tehran, Iran

<sup>2</sup> Associate Professor, Dental Research Center, Dentistry Research Institute, Tehran University of Medical Sciences, Tehran, Iran, AND Department of Oral Medicine, School of Dentistry, Tehran University of Medical Sciences, Tehran, Iran

<sup>3</sup> PhD, Nanotechnology Research Centre, School of Pharmacy, Tehran University of Medical Sciences, Tehran, Iran

<sup>4</sup> Oral and Maxillofacial Medicine Specialist, Department of Oral Medicine, School of Dentistry, Tehran University of Medical Sciences, Tehran, Iran

### Abstract

**Introduction:** Oral lichen planus (OLP) is an autoimmune disease with uncertain etiopathogenecity and no definitive treatment. Considering the recurrent nature of OLP, finding an adjunctive treatment to minimize the risk of chronicity and recurrence of OLP and to decrease the adverse effects of corticosteroids can be promising. This study aimed to assess the efficacy of a mixture of hyaluronic acid and triamcinolone in the treatment of OLP.

**Case Presentation:** This study involved five OLP patients. In each patient, the mixture of hyaluronic acid/triamcinolone was injected intralesionally into the case lesion, while triamcinolone alone was injected into the control lesion. The patients were followed-up at 14 and 28 days post-intervention and then monthly for 9 months. Recurrences were observed in three control lesions, while the patients did not show any aggravation or recurrence in the case lesions.

**Conclusion:** It appears that triamcinolone/hyaluronic acid mixture is potentially beneficial in the treatment of OLP.

**Key Words:** Oral Lichen Planus, Hyaluronic Acid, Triamcinolone

✉ Corresponding author:  
Kh. Akbari, Oral and  
Maxillofacial Medicine  
Specialist, Department of Oral  
Medicine, School of Dentistry,  
Tehran University of Medical  
Sciences, Tehran, Iran

kh\_akbari@yahoo.com

Received: 12 March 2017

Accepted: 25 May 2018

Journal of Islamic Dental Association of IRAN (JIDAI) Summer 2018 ;30, (3)

### Introduction

Oral lichen planus (OLP) is a chronic, inflammatory autoimmune disease with unknown etiology. In contrast to cutaneous lesions, oral lesions rarely heal spontaneously, have a high resistance to local and systemic treatments, and are a potential source of significant morbidity [1].

The malignant transformation potential of OLP reported in 0.4% to 5% of the patients is a major concern for patients and clinicians [2].

Corticosteroids are the first choice of drug for OLP. However, due to adverse side effects such as

glucose intolerance, hypertension, pancreatitis, osteoporosis, adrenal insufficiency, and interferences with pregnancy and nursing as well as gastrointestinal (GI), neurological, and psychological disorders, an adjunct modality to minimize these side effects and improve their efficacy can be highly favorable for patients [3,4]. Hyaluronan, as an important component of the extracellular matrix of vertebrates, plays an important role in many biological processes such as cell signaling, morphogenesis, matrix organization, tissue hydration, lubrication, wound

healing, regulation of gene expression, and cell proliferation [5-7].

In the current study, we mixed hyaluronic acid with triamcinolone to enhance the efficacy of triamcinolone and to eliminate or decrease its side effects in the treatment of symptomatic OLP lesions, aiming to enhance the recovery of lesions and postpone their recurrence

### Case Presentation

This technical case report involved five OLP patients presenting to the Oral and Maxillofacial Medicine Department, School of Dentistry, Tehran University of Medical Sciences, Tehran, Iran, who met the following inclusion criteria and had none of the exclusion criteria. The inclusion and exclusion criteria set for this study were approved by two clinicians [8].

#### *Inclusion criteria:*

- Bilateral presence of white reticular-papular lesions.
- Histopathological criteria such as hydropic (liquefactive) degeneration of the basal layer, band-like infiltration of mononuclear inflammatory cells in the superficial connective tissue.
- The erosive-ulcerative form of the lesion and the atrophic-erythematous form of the lesion.

#### *Exclusion criteria:*

- Dysplasia.
- Use of any topical, local, or systemic medications.
- Systemic diseases.
- History of chemotherapy.
- History of radiotherapy.
- Pregnancy/nursing.
- History of allergy to hyaluronic acid.

#### *Case No. 1:*

A 34-year-old male complaining of lesions that developed six months ago with burning sensation and pain during deglutition and eating, severely interfering with his daily activities. He had not received any treatment for this condition (Figures 1 and 2).

#### *Case No. 2:*

A 65-year-old female with an approximately 20-year history of OLP. She had not sought any treatment for this condition. She experienced pain and burning sensation at the site of lesions during the past couple of months.

#### *Case No. 3:*

A 40-year-old female suffering from OLP for about one year. She complained of pain and burning sensation at the site of lesions.

#### *Case No. 4:*

A 54-year-old female with a four-year history of OLP complaining of pain during eating, bleeding during tooth brushing, and intolerance of spicy and sour foods.

#### *Case No. 5:*

A 60-year-old male complaining of OLP. He had the lesions for about one year and complained of pain and burning sensation.

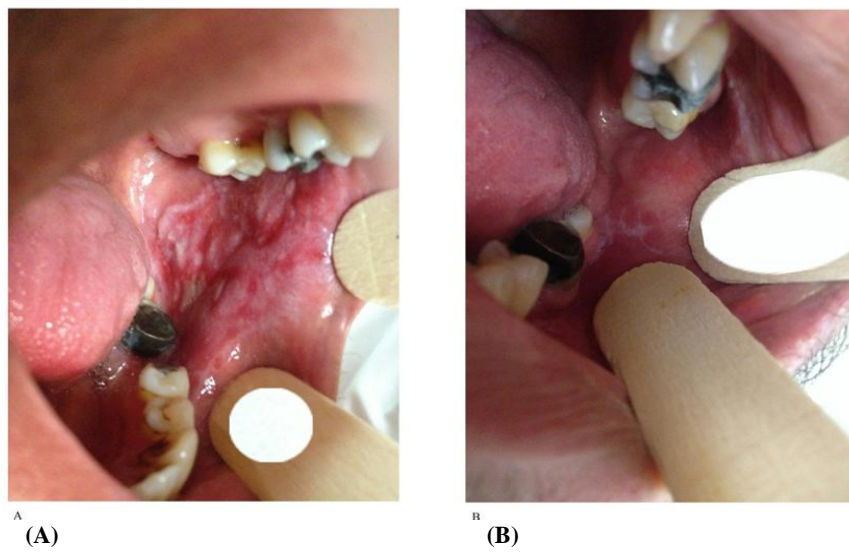
Table 1 lists the clinical characteristics of the case and control lesions in each patient.

All the patients underwent the following tests: fasting blood sugar (FBS), Hepatitis C antibody (HCV Ab), thyroxine (T4), triiodothyronine (T3), thyroid-stimulating hormone (TSH), folic acid, zinc, B12, ferritin, serum iron, total iron-binding capacity (TIBC), and complete blood count (CBC, diff.) [9].

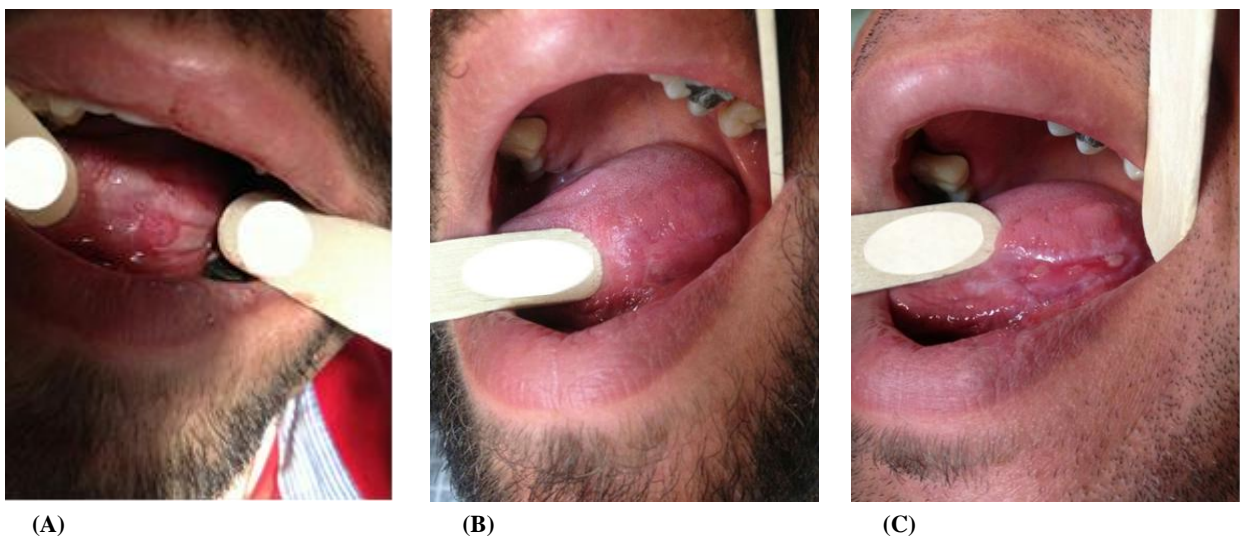
The Ethics Committee of Tehran University of Medical Sciences approved the study protocol. The patients were briefed about the study and signed informed consent forms.

First, OLP lesions were measured in millimeters (mm) using a caliper, and the largest diameter of the lesion was chosen as the size of the lesion. In each patient, the larger lesion or the one with a more severe type, e.g. erosive/ulcerative versus atrophic, was considered as the case, while the smaller lesion or the one with a lower severity was considered as the control lesion.

To prepare the hyaluronic acid powder, Hyaluron Hexal solution (HEXAL AG., Industriestraße 25, Holzkirchen, Germany) was freeze-dried (Christ, Germany). In the case group, 7 mg of sterilized hyaluronic acid powder was dissolved in one vial (40 mg/ml) of triamcinolone acetonide (Iran Hormone Co., Tehran, Iran) per each 20 mm of the lesion. The drug mixture was injected into the case lesion, while triamcinolone alone was injected into the control lesion. The patients were then followed-up at 14 and 28 days and at two, three, four, five, six, seven, eight, and nine months post-intervention (a total of 10 sessions).



**Figure 1.** (A) Case lesion before treatment. (B) Case lesion after 9 months of treatment



**Figure 2.** (A) Control lesion before treatment (B) Control lesion after 2 weeks of treatment (C) Recurrence of the control lesion after 3 months of treatment

**Table 1.** Clinical characteristics of the case and control lesions in each patient

	Type of lesion	Site of lesion	Size lesion (mm)	F 1	F 2	F 3	F 4	F 5	F 6	F 7, F 8, F 9	F 10				
				Type	Size (mm)	Type	Size (mm)	Type	Size (mm)	Type	Size (mm)	Type	Size (mm)		
Case 1	Case	Keratotic Erosive/ulcerative Atrophic/erythematous	Left buccal mucosa	50	Keratotic Atrophic/erythematous Erosive	36	Keratotic Atrophic/erythematous	22	No change	“	“	Keratotic	12	No change	“
	Control	Keratotic Erosive/ulcerative	Left lateral border of the tongue	35	Keratotic	20	Keratotic	10	No change	Erosive/ulcerative Keratotic	50				
Case 2	Case	Keratotic Erosive/ulcerative	Left vestibule and buccal mucosa	20	Atrophic/erythematous	11	No lesion	“	“	“	“	“	“	“	“
	Control	Keratotic Atrophic/erythematous	Right buccal mucosa	12	No lesion	“	“	“	“	Keratotic Atrophic/erythematous	10				
Case 3	Case	Keratotic Erosive	Right vestibule and buccal mucosa	27	Keratotic Erosive	16	No lesion	“	“	“	“	“	“	“	“
	Control	Keratotic Atrophic/erythematous	left vestibule and buccal mucosa	32	Keratotic Atrophic/erythematous	20	Keratotic	20	No lesion	“	“	“	“	“	“
Case 4	Case	Keratotic Erosive/ulcerative Atrophic/erythematous	Right palatal mucosa	30	Atrophic/erythematous	10	No lesion	“	“	“	“	“	“	“	“
	Control	Keratotic Atrophic/erythematous	Left palatal mucosa	35	No lesion	“	“	“	“	“	“	“	“	“	“
Case 5	Case	Keratotic Erosive Atrophic/erythematous	Left buccal mucosa	30	Keratotic	22	No change	No lesion	“	“	“	“	“	“	“
	Control	Keratotic Atrophic/erythematous	Left lateral border of the tongue	32	Keratotic	11	No change	“	“	Keratotic	20	Keratotic Atrophic/erythematous	22		

F=Follow-up

## Discussion

The suggested mechanism for the pathogenesis of OLP is the involvement of T-cell-mediated immune responses [9].

To exclude common autoimmune disorders related to OLP such as Hashimoto's thyroiditis and pernicious anemia as well as certain types of OLP related to HCV and to eliminate the impact of factors such as diabetes and iron deficiency on healing processes, all the patients were examined for FBS, HCV Ab, T4, T3, TSH, folic acid, zinc, B12, ferritin, serum iron, TIBC, and CBC (diff.) [9].

Topical corticosteroids are the first choice of treatment due to having fewer side effects and optimal efficacy similar to or even superior to that of systemic steroids [10,11]. However, due to the chronic nature and high recurrence rate of OLP, treatment of this condition requires frequent and long-term local/topical use of corticosteroids with side effects such as candidiasis, mucosal thinning, tachyphylaxis, delayed healing, discomfort following application, and poor patient cooperation [11,12]. Hyaluronic acid has also been used for the treatment of vaginal atrophy in middle-aged women [13].

It appears that the significant improvement and no recurrence at the 9-month follow-up in the present five cases were due to the significant role of hyaluronic acid in the improvement of tissue atrophy. Also, by simultaneous use of hyaluronic acid and triamcinolone, we may be able to prevent atrophy following the use of triamcinolone, which has been reported in previous studies [11]. It should be noted that these results were obtained despite differences in the size of case and control lesions and their severity (an ulcerative/erosive case lesion versus a reticular, atrophic/erosive control lesion). Thus, it may be concluded that the efficacy of the mixture of hyaluronic acid and triamcinolone is much higher than that of triamcinolone alone.

Studies on the therapeutic efficacy of hyaluronic acid in the treatment of OLP are limited. Nolan et al [14] evaluated the efficacy of hyaluronic acid in the treatment of OLP and reported a significant reduction in soreness (for up to four hours after administration) compared to the placebo group and

also reported a reduction in the size of lesions 28 days after the treatment compared to the baseline. Shetty et al [15] showed a significant reduction in the visual analog scale (VAS) score of pain, degree of erythema, and size of the lesion in the case group compared to the control group.

Evidence shows that hyaluronic acid exerts anti-inflammatory effects by drainage of metalloproteinases, prostaglandins, and other bioactive molecules and has anti-edematous effects due to its osmotic activity [16].

We may conclude that the anti-inflammatory and anti-edematous effects of hyaluronic acid and the anti-inflammatory effects of triamcinolone are synergistic when used together for the treatment of OLP. It may be assumed that the absence of recurrence in the case lesions of the current study may be due to the reinforced anti-inflammatory effects of the combination of triamcinolone and hyaluronic acid. Therefore, considering the inflammatory and chronic nature of OLP, this mixture can be effective in the treatment of OLP.

The patients treated in this study did not show any aggravation of the disease or recurrence in the case group during the nine-month follow-up. It appears that the triamcinolone/hyaluronic acid mixture has the potentially beneficial properties of hyaluronic acid and thus can be a promising modality for the treatment of OLP. It should be noted that this result was obtained in the current study despite the fact that larger and more severe lesions were assigned to the case group and were treated with the mentioned mixture, while smaller and less severe lesions were assigned to the control group and were treated with triamcinolone alone. Thus, randomized clinical trials on larger sample sizes are required to confirm the efficacy of the mixture of triamcinolone and hyaluronic acid in the treatment of OLP.

## Conclusion

Considering the important role of hyaluronic acid in tissue healing, it can be concluded that a combination of hyaluronic acid and triamcinolone with reinforced anti-inflammatory characteristics can be an effective modality for the treatment of OLP and to reduce its recurrence.

## References

1. Agha-Hosseini F, Borhan-Mojabi K, Monsef-Esfahani HR, Mirzaii-Dizgah I, Etemad-Moghadam S, Karagah A. Efficacy of purslane in the treatment of oral lichen planus. *Phytother Res.* 2010 Feb;24(2):240-4.
2. Eisen D. The clinical features, malignant potential, and systemic associations of oral lichen planus: a study of 723 patients. *J Am Acad Dermatol.* 2002 Feb;46(2):207-14.
3. Buchman AL. Side effects of corticosteroid therapy. *J Clin Gastroenterol.* 2001 Oct;33(4):289-94.
4. Stanbury RM, Graham EM. Systemic corticosteroid therapy--side effects and their management. *Br J Ophthalmol.* 1998 Jun;82(6):704-8.
5. Chang CY, Chan AT, Armstrong PA, Luo HC, Higuchi T, Strehin IA, et al. Hyaluronic acid-human blood hydrogels for stem cell transplantation. *Biomaterials.* 2012 Nov;33(32):8026-33.
6. Han L, Zhao Y, Yin L, Li R, Liang Y, Huang H, et al. Insulin-loaded pH-sensitive hyaluronic acid nanoparticles enhance transcellular delivery. *AAPS PharmSciTech.* 2012 Sep;13(3):836-45.
7. Prestwich GD. Hyaluronic acid-based clinical biomaterials derived for cell and molecule delivery in regenerative medicine. *J Control Release.* 2011 Oct 30;155(2):193-9.
8. van der Meij EH, van der Waal I. Lack of clinicopathologic correlation in the diagnosis of oral lichen planus based on the presently available diagnostic criteria and suggestions for modifications. *J Oral Pathol Med.* 2003 Oct; 32(9):507-12.
9. Agha-Hosseini F, Mirzaii-Dizgah I, Mohammadpour N. Muscarinic cholinergic receptors (MR3) in saliva of patients with oral lichen planus. *Arch Dermatol Res.* 2016 Sep; 308(7):481-6.
10. Thongprasom K, Dhanuthai K. Steroids in the treatment of lichen planus: a review. *J Oral Sci.* 2008 Dec;50(4):377-85.
11. Xiong C, Li Q, Lin M, Li X, Meng W, Wu Y, et al. The efficacy of topical intralesional BCG-PSN injection in the treatment of erosive oral lichen planus: a randomized controlled trial. *J Oral Pathol Med.* 2009 Aug;38(7):551-8.
12. Agha-Hosseini F, Moslemi E, Mirzaii-Dizgah I. Comparative evaluation of low-level laser and CO<sub>2</sub> laser in treatment of patients with oral lichen planus. *Int J Oral Maxillofac Surg.* 2012 Oct; 41(10):1265-9.
13. Jokar A, Davari T, Asadi N, Ahmadi F, Foruhari S. Comparison of the Hyaluronic Acid Vaginal Cream and Conjugated Estrogen Used in Treatment of Vaginal Atrophy of Menopause Women: A Randomized Controlled Clinical Trial. *Int J Community Based Nurs Midwifery.* 2016 Jan; 4(1):69-78.
14. Nolan A, Badminton J, Maguire J, Seymour RA. The efficacy of topical hyaluronic acid in the management of oral lichen planus. *J Oral Pathol Med.* 2009 Mar;38(3):299-303.
15. Shetty RR, Burde KN, Guttal KS. The Efficacy of Topical Hyaluronic Acid 0.2% in the Management of Symptomatic Oral Lichen Planus. *J Clin Diagn Res.* 2016 Jan;10(1):ZC46-50.
16. Penning LI, de Bie RA, Walenkamp GH. Subacromial triamcinolone acetonide, hyaluronic acid and saline injections for shoulder pain an RCT investigating the effectiveness in the first days. *BMC Musculoskelet Disord.* 2014 Oct 23;15:352.